

## Primary lymphoma of colon: a case report

Cem Çekiç<sup>1</sup>, Zeynep Zehra Gümüş<sup>2</sup>, Hüseyin Sinan Akay<sup>1</sup>, Firdes Ünal<sup>1</sup>, Füsün Özdemirkıran<sup>3</sup>, Sezgin Vatanserver<sup>1</sup>, Belkıs Ünsal<sup>1</sup>

<sup>1</sup>Department of Gastroenterology, Atatürk Training and Research Hospital, Izmir, Turkey

<sup>2</sup>Department of Internal Medicine, Atatürk Training and Research Hospital, Izmir, Turkey

<sup>3</sup>Department of Hematology, Atatürk Training and Research Hospital, Izmir, Turkey

### Abstract

One-third of all extranodal lymphomas are located in the gastrointestinal tract, and 10-20% of gastrointestinal lymphomas are located in the colon. Primary colorectal lymphomas constitute 0.1-0.5% of all large bowel malignancies. The most common type of lymphoma is diffuse large B cell lymphoma. It is twice as common in males than females and generally is encountered in the 6<sup>th</sup> and 7<sup>th</sup> decades. Abdominal pain and weight loss are the most common symptoms, and because of these non-specific symptoms, the diagnosis is usually delayed. Isolated surgical therapy or chemotherapy can be employed; also a combination treatment might be preferred. In this case report, we aimed to present a colonic non-Hodgkin lymphoma (NHL) patient who was admitted with weight loss and abdominal pain. Presentation of the case was at an earlier age relative to the literature. Also, we discussed the treatment of the patient.

**Key words:** primary colorectal, lymphoma.

Address for correspondence:

Cem Çekiç, Department of Gastroenterology, Atatürk Training and Research Hospital, 35360 Izmir, Turkey, e-mail: cekiccem@yahoo.com

### INTRODUCTION

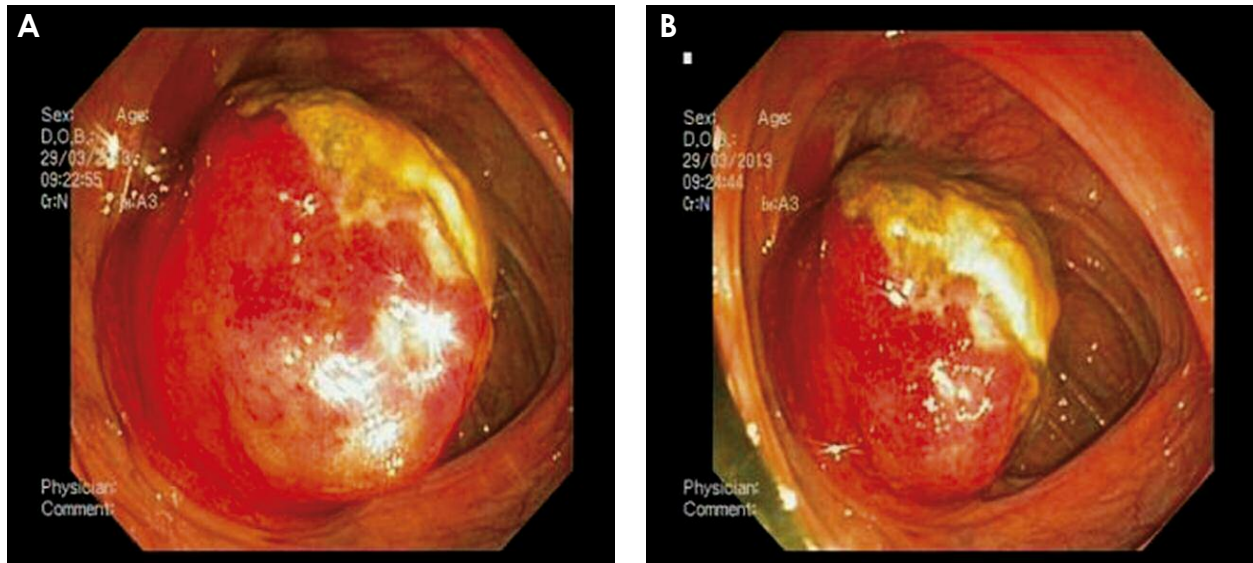
The large bowel is the most common localization for the GI lymphomas, followed by the stomach and the small intestine [1]. The diagnosis is usually delayed because of non-specific symptoms such as abdominal pain and weight loss. Due to the abundance of lymphoid tissue, colorectal lymphomas generally occur in the cecum and less frequently in the rectum [2]. Although the etiological factors are unclear, in immunosuppressive situations, such as HIV infection or after organ transplantation the frequency of NHL increases [3]. The main determining factor of prognosis is the stage of lymphoma, and overall 5-year survival is 67% [4].

### CASE REPORT

A twenty-nine-year-old man was admitted to the gastroenterology clinic with abdominal pain and weight loss. Neither regular use of drugs nor a systemic disease was present in his past history. On physical examination, right lower abdominal tenderness was determined. His complete blood count and rou-

ne biochemical tests were within normal limits. Ultrasonographic examination showed a hypoechoic mass lesion which is 5 × 4 cm in size and is adjacent to the proximal ascending colon. Colonoscopy revealed a polypoid mass lesion which is 5 × 5 cm in size with a mucosal ulceration in the cecum. The lesion was biopsied. Thorax CT examination showed no pathologic findings and on the abdominal CT there was not any other pathological finding besides the mass in the cecum. His tumor markers were in the normal range. Endoscopic biopsy was reported as diffuse large B cell lymphoma. The patient was consulted by the hematology clinic and, bone marrow aspiration was reported to be normocellular. Serologic data regarding HIV and Epstein-Barr Virus were negative. Positron emission tomography (PET) for staging revealed an increased 18F-FDG uptake at the localization of the cecal mass. There were also an increased 18F-FDG uptake at the lymph nodes adjacent to the mass and second lumbar vertebral body and they were evaluated as metastases.

According to the Ann Arbor classification, the patient was recognized as stage 4 extranodal non-Hodgkin lymphoma. The R-CHOP (rituximab, cyclophosphamide, hydroxydaunorubicin, vincristine,



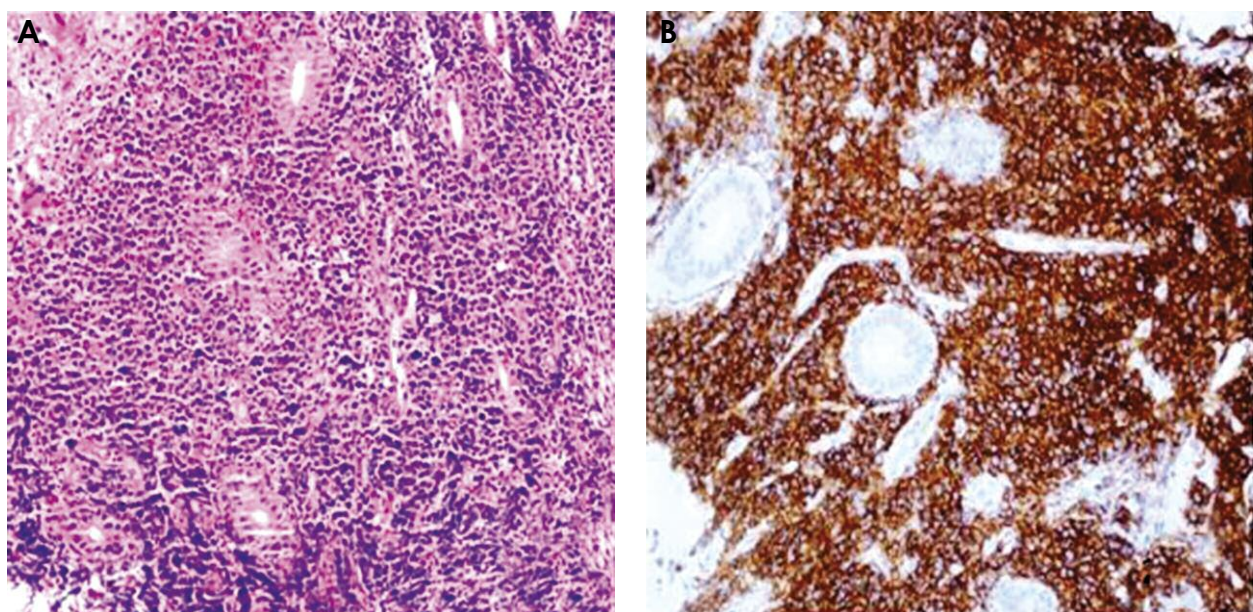
**Fig. 1A, B.** Colonoscopic view: Polypoid mass with surface ulceration on the cecum

prednisone) chemotherapy treatment was commenced. After 4 courses of chemotherapy, the patient was planned to be evaluated for systemic and local lymphoma involvement with PET and colonoscopy.

## DISCUSSION

In the colorectal lymphoma treatment, the role of surgery is not well established. However, surgical intervention helps to determine the stage of the tumor, predict the prognosis and prevent complications such as tumor perforation [5]. The surgical treatment is usually

preferred in the early stage disease. But for advanced stage disease, solely chemotherapy or a combination of treatments including both chemotherapy and surgery is chosen. Radiation therapy is applied to a small number of selected cases [6]. In recent years, with the use of antiCD-20 monoclonal antibody for lymphoma treatment, the success of this highly chemosensitive tumor treatment has been increased and surgical treatment requirements have been decreased [7]. Consequently, even though it is rare, we should consider lymphoproliferative diseases in cases with complaints such as abdominal pain and weight loss, a colorectal mass identified on colonoscopy, and especially enlarged lymph nodes adjacent to the mass.



**Fig. 2A, B.** Histopathological findings: Immunohistochemically neoplastic cells: cytokeratin 116 (-), CD 3 (-), TaT (-), CD 20 (+). Ki proliferation index: 95%

## REFERENCES

---

1. Times M. Colorectal lymphoma. *Clin Colon Rectal Surg* 2011; 24: 135-141.
2. Stanojevic GZ, Nestorovic MD, Brankovic BR, et al. Primary colorectal lymphoma: an overview. *World J Gastrointest Oncol* 2011; 3: 14-18.
3. Wong MT, Eu KW. Primary colorectal lymphomas. *Colorectal Dis* 2006; 8: 586-591.
4. American Cancer Society Cancer Facts and Figures 2010. American Cancer Society; Atlanta 2010.
5. Fan CW, Changchien CR, Wang JY, et al. Primary colorectal lymphoma. *Dis Colon Rectum* 2000; 43: 1277-1282.
6. Avilés A, Neri N, Huerta-Guzmán J. Large bowel lymphoma: an analysis of prognostic factors and therapy in 53 patients. *J Surg Oncol* 2002; 80: 111-115.
7. Morrison VA. Evolution of R-CHOP therapy for older patients with diffuse large B-cell lymphoma. *Expert Rev Anticancer Ther* 2008; 8: 1651-1658.